

# TACE - Metastase eines Aderhautmelanom

Rupert Horst Portugaller  
Univ. Klinik f. Radiologie, MUG  
Abt. f. Vaskuläre u. Interventionelle Radiologie

Aderhautmelanom  
**Background**

Uvea Melanom (Aderhautmelanom):

- 5% aller Melanome
- Ca. 60% isolierte Lebermetastasen
- Primärtumor Lebermetastasen: median 36 Mo Zeitintervall
- 2-7 Mo ÜL nach Metastasendetektion

Wöll E et al. Uveal melanoma: natural history and treatment options for metastatic disease. *Melanoma res* 1999; 9:575-581

Gragoudas ES et al. Survival of patients with metastases from uveal melanoma. *Ophthalmology* 1991; 98:383-389

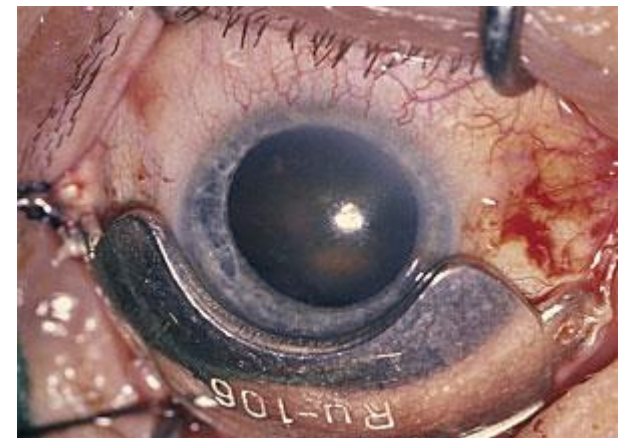
# Fotemustin

- **Fotemustin**, chemisch **1-(2-Chlorethyl)-3-(1-diethoxyphosphorylethyl)-1-nitrosoharnstoff** (Handelsname: Muphoran<sup>®</sup>)
- Mitosehemmer

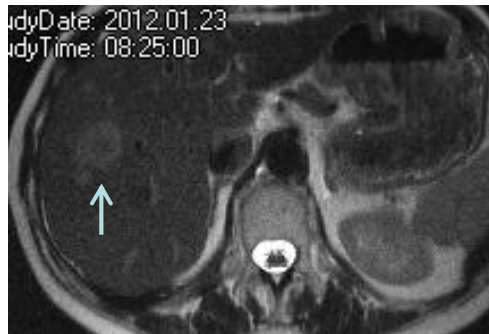# Patientendaten

72-j Frau

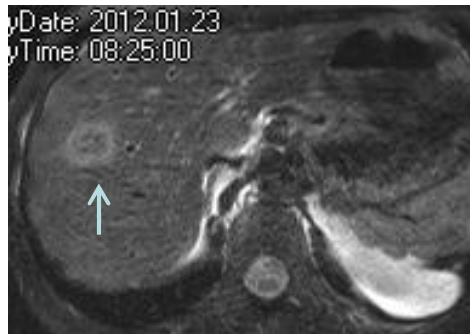
- 01/2009: Aderhautmelanom li Auge;  
Radiatio mit Ruthenium Applikator
- 10/2011: Multiple Filiae hepatitis (33 mo  
nach Primärtumordiagnose)
- 12/2011 bis 02/2012: Syst.  
Kombinationstherapie mit  
Fotemustin und Sorafenib;  
Abbruch wegen Leukopenie  
und Transaminasen



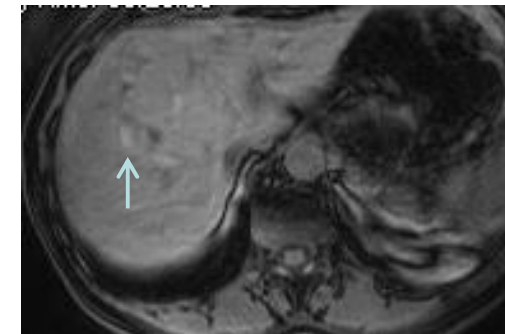
Aderhautmelanom Metastasen Case  
MRT vom 23.01.2012



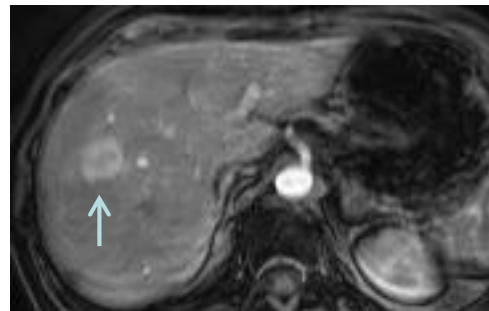
T2



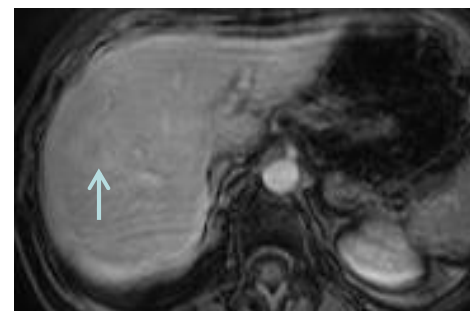
T2 fs



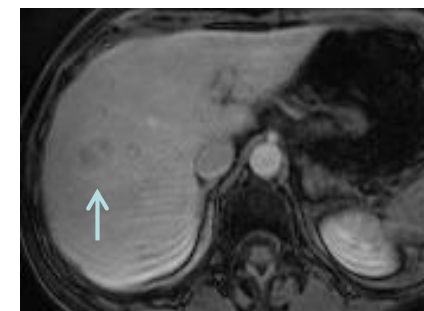
T1 fs



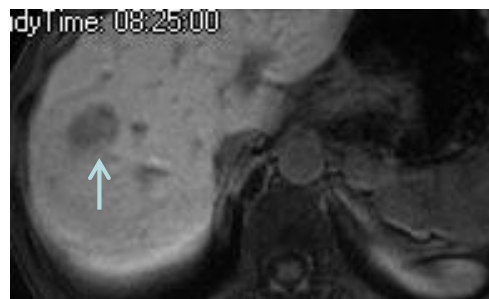
CE art



CE PV



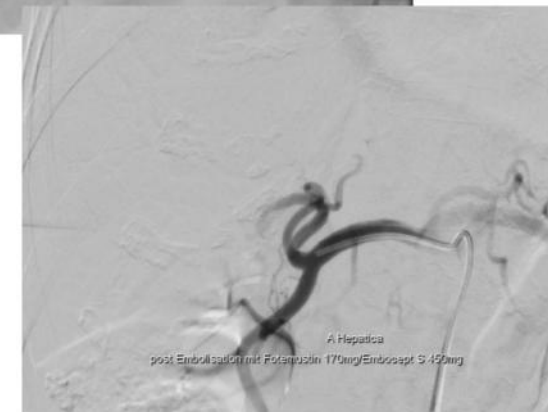
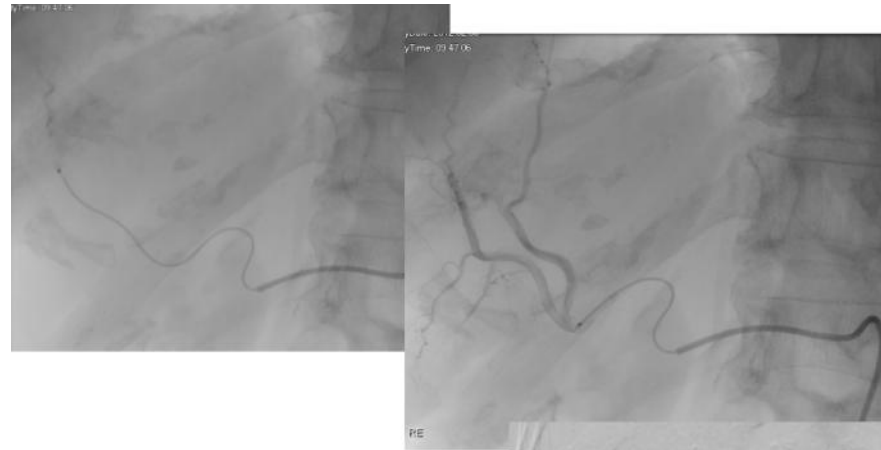
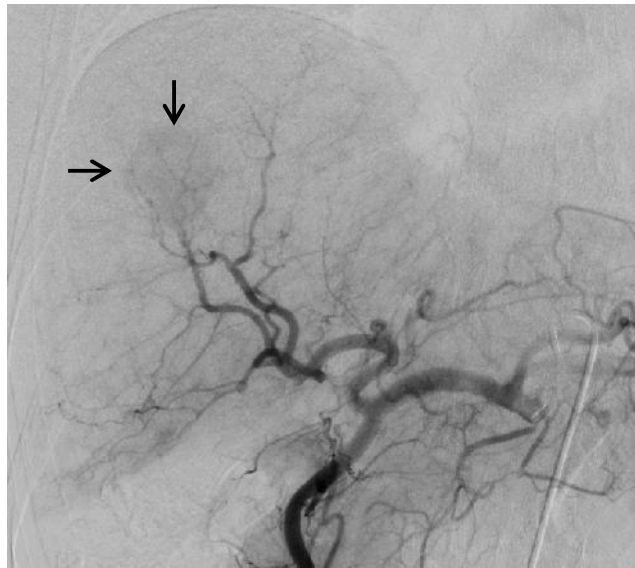CE venös



Primovist Spätphase

Filia hepatis, 2.7 cm DM

# Aderhautmelanom Metastasen Case TACE, 08.02.2012

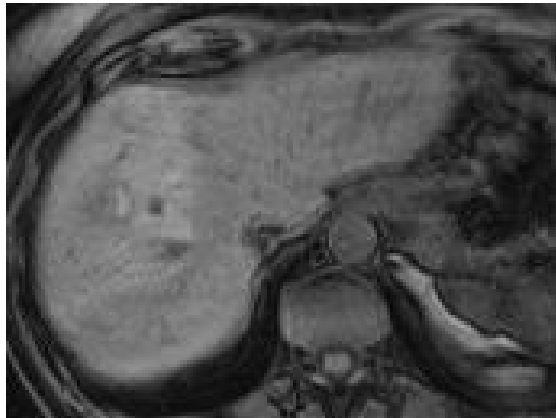

TACE:  
170mg Fotemustin<sup>1</sup>/ 450mg Embocept S/ KM,  
0.027 Inch High-Flow Renegade Kath.,  
Fathom Draht  
Komplikationslose postinterventionelle Phase

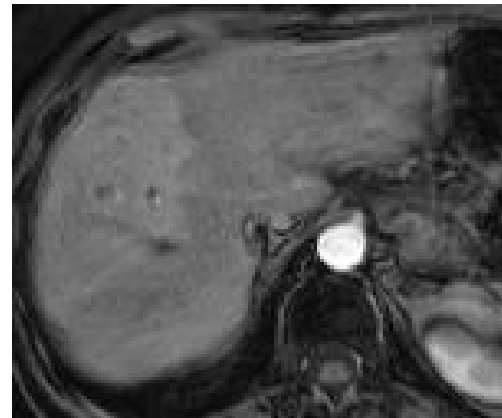
<sup>1</sup>100mg/m<sup>2</sup>; Referenz:

Schuster R et al. Transarterial chemoembolization of liver metastases from uveal melanoma after failure of systemic therapy: toxicity and outcome. *Melanoma Research* 2010; 20:191-196

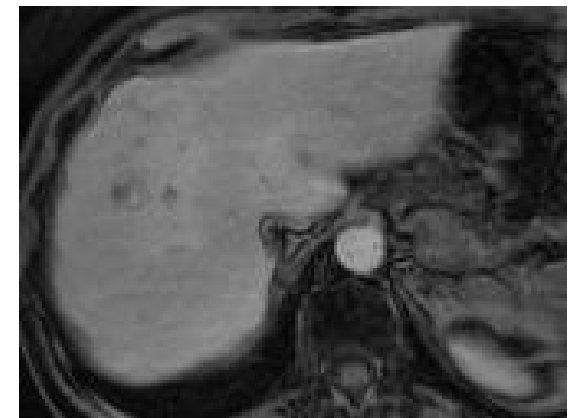
Aderhautmelanom Metastasen Case  
MRT, 09.05.2012



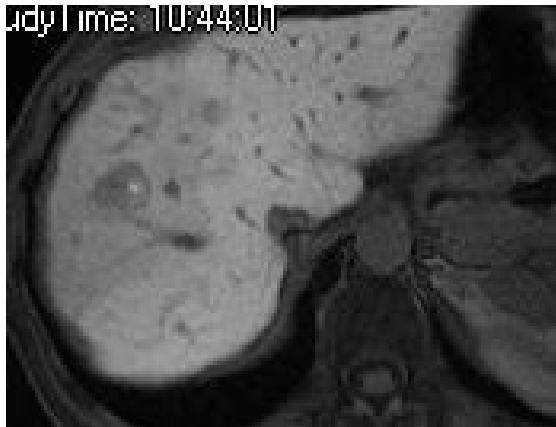
T1 fs



CE art



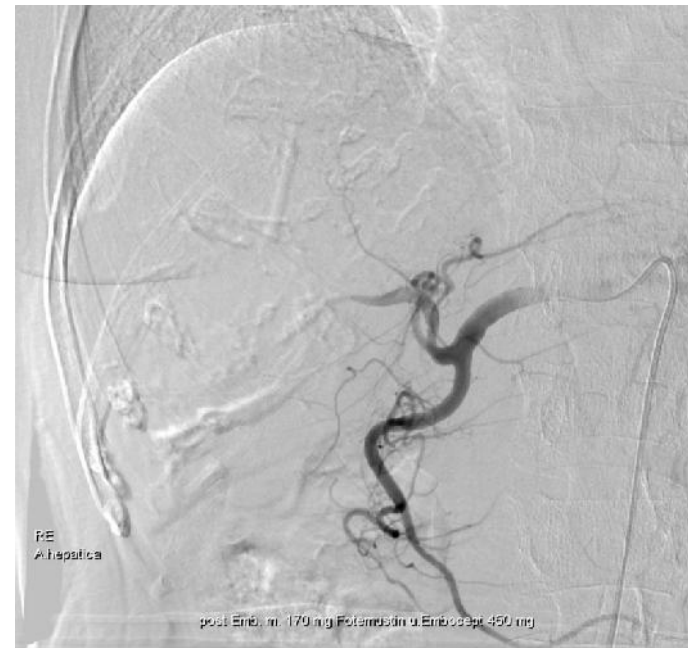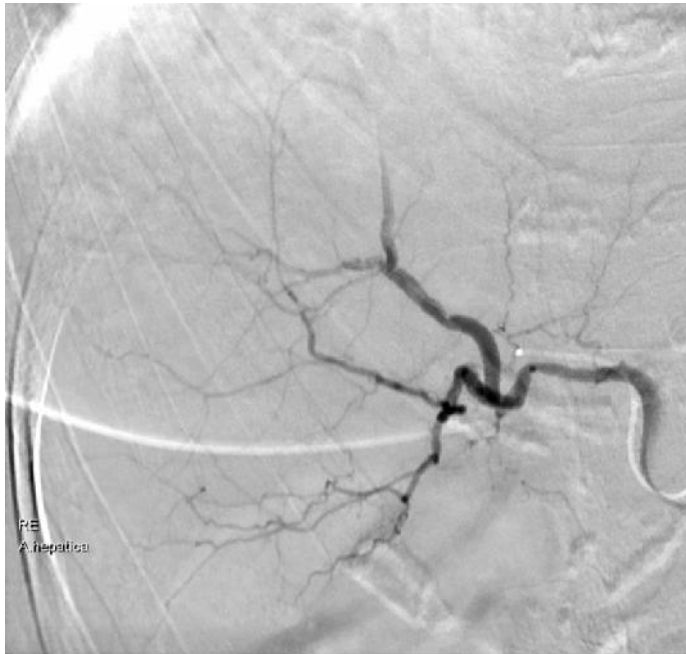CE venös



Primovist Spätphase

# Aderhautmelanom Metastasen Case

## 2. TACE, 12.06.2012

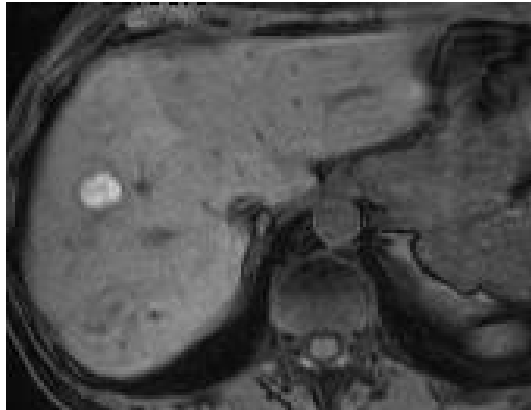


### 2. TACE:

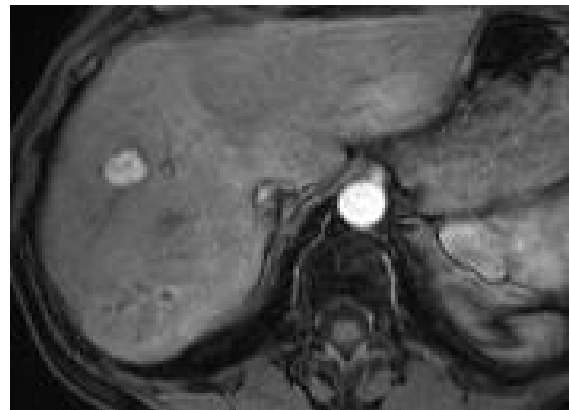170mg Fotemustin/ 450mg Embocept S/ KM,  
0.027 Inch High-Flow Renegade Kath.,  
Fathom Draht  
Komplikationslose postinterventionelle Phase



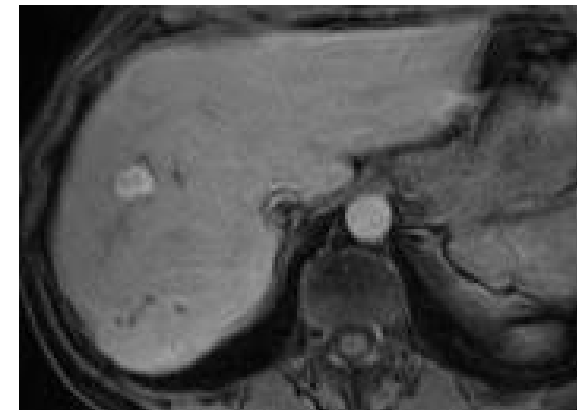
Aderhautmelanom Metastasen Case  
**MRT, 09.07.2012**



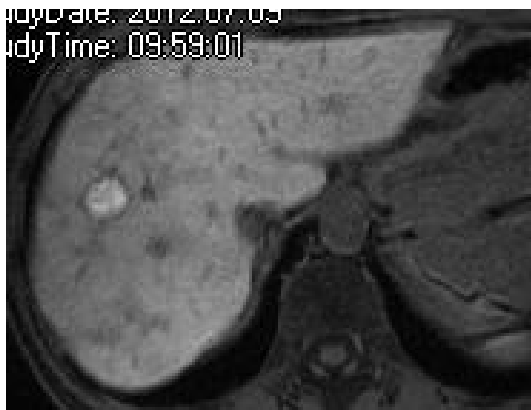T1 fs



CE art



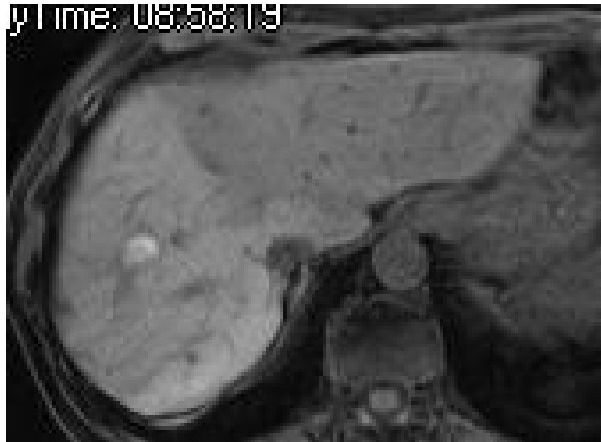CE venös



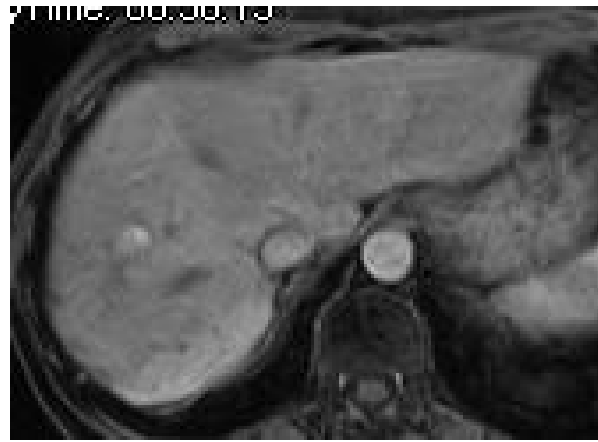Primovist Spätphase

# Aderhautmelanom Metastasen Case

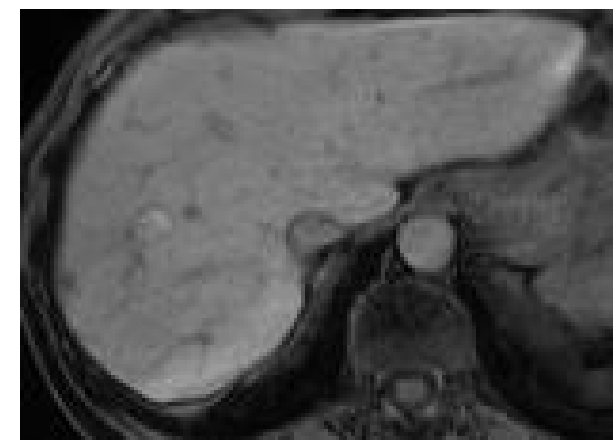
## MRT, 03.10.2012



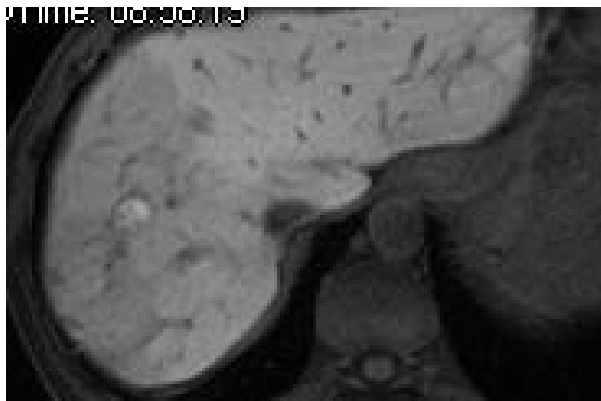T1 fs



CE art



CE venös

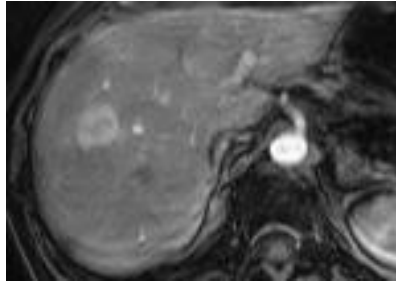


Primovist Spätphase

8 Monate post 1. TACE:  
Filia hepatis ohne KM-  
Aufnahme,  
1,6 cm DM

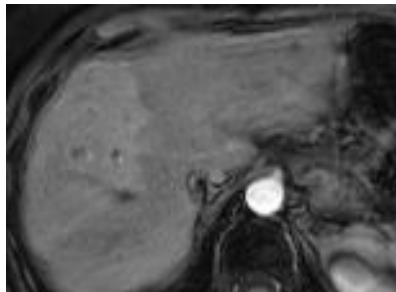
# Ergebnis:

23.01.2012



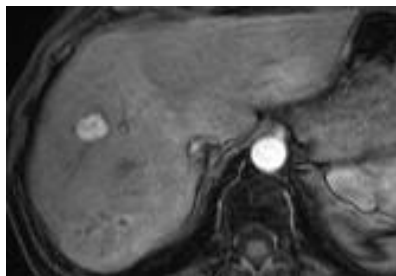
8 Monate post 1. TACE:  
DM-Abnahme der Filia von  
2,7 cm 1,6 cm (40%)

09.05.2012



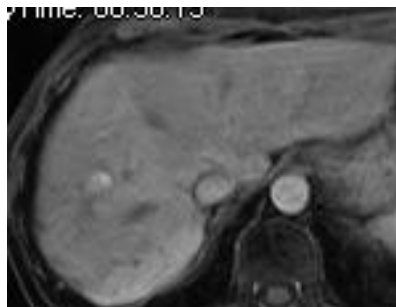
Partieller Respons (RECIST)

09.07.2012



Primärtumordiagnose: 01/2009  
48 Monate ÜL dzt.

03.10.2012



Erstdiagn. der Fil. hepatitis:  
10/ 2011 15 Mo ÜL dzt.

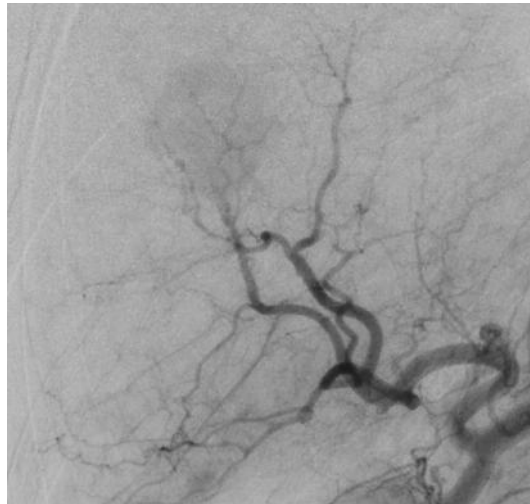Pat. dzt. in gutem AZ,  
beschwerdefrei

# Literature:

- 21 pat. with hep. metast. from uveal melanoma
- TACE with 50 mg/m<sup>2</sup> fotemustine/ 10ml lipiodol/ (300-500 od. 500-700µm PVA-particles)
- Median 3.29 (1-6) interventions/pat.
- 17.3 mo mean follow-up
- 14% partial respons, 29% stable disease, 57% progressive disease
- Mean survival after prim-tu diagnosis: 40.7 mo
- Mean survival after hep. metast. diagn.: 28.7 mo

# Aderhautmelanom Metastasen

## Cave!

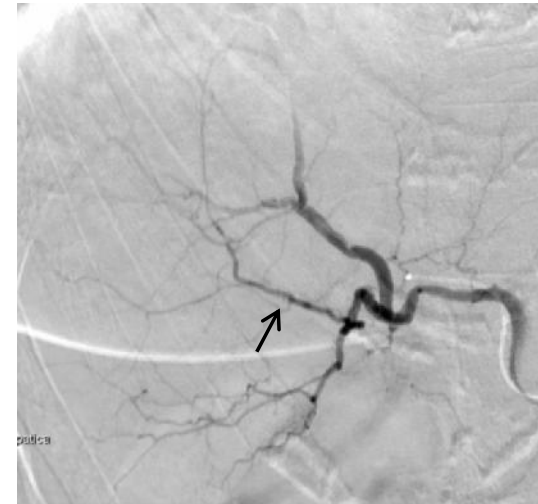

1. TACE

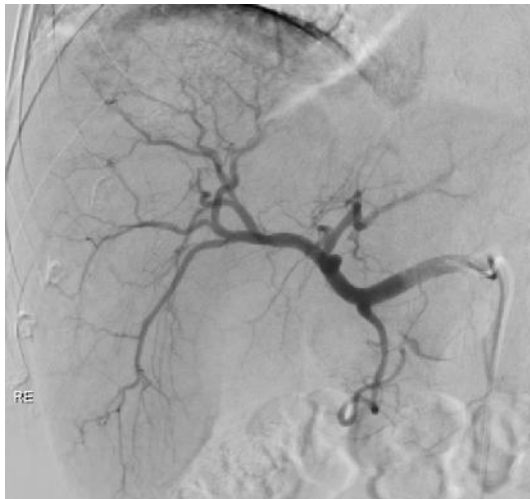Aktuelle Pat.



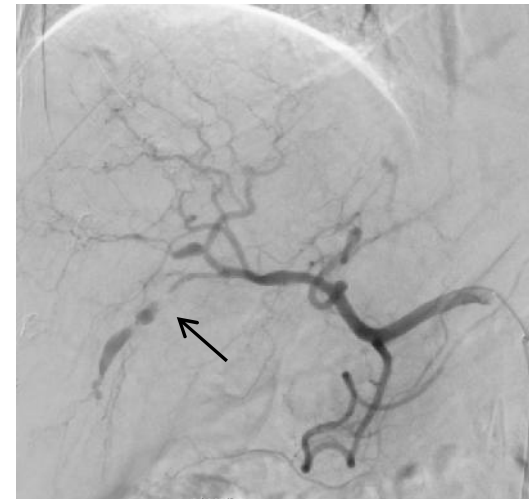Uvea-Melanom;  
Fotemustin:  
100mg/m<sup>2</sup>



4 Monate später

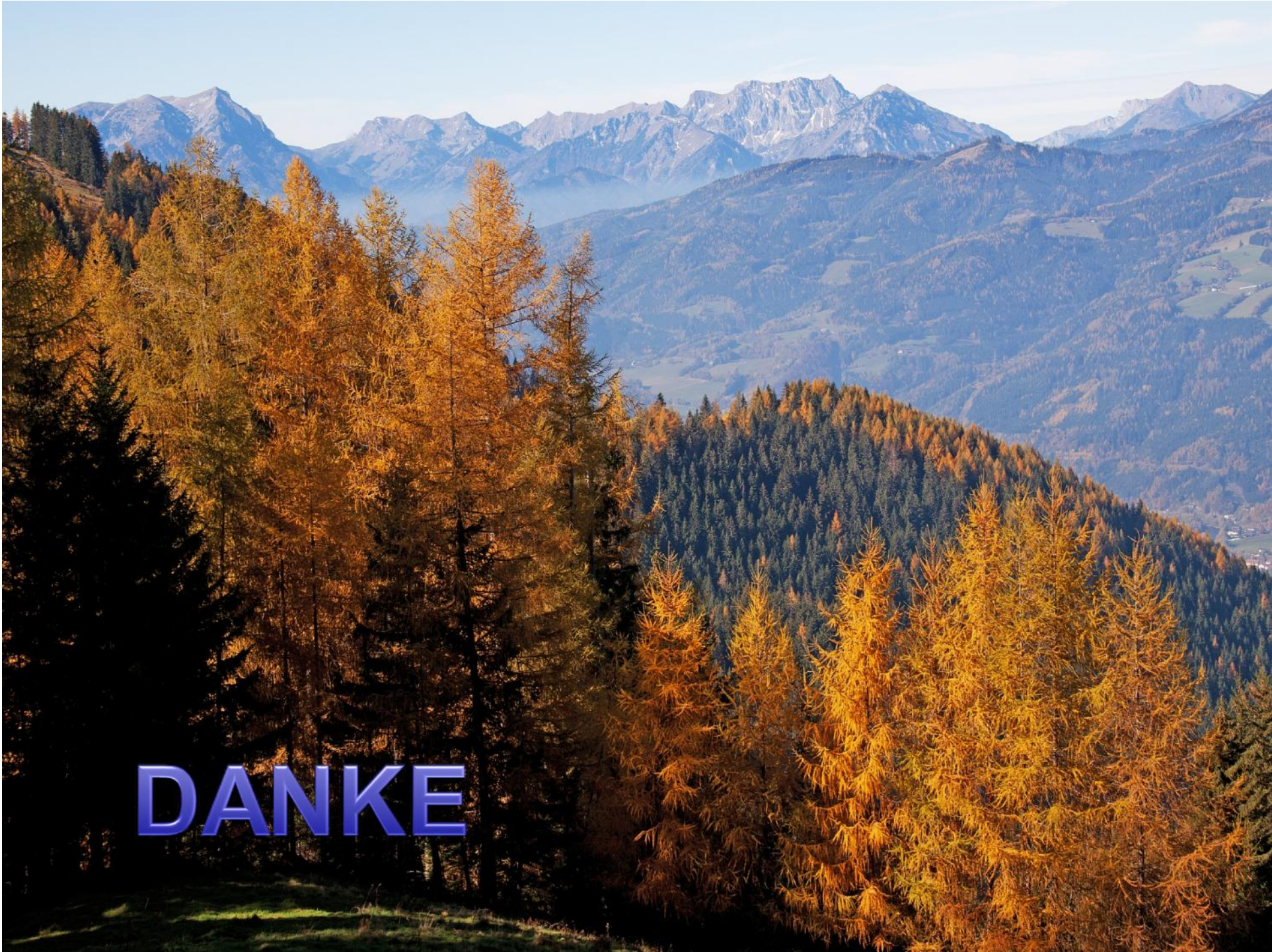

Anderer Pat.



# Cave!

- Potentielle Gefäßschädigung durch Fotemustin?
- Referenz für Dosierung von Fotemustin:  
Körperoberfläche oder zu embolisierendes Lebervolumen?



**DANKE**